

## Case Report

# Interim three-dimensional printed overlay prosthesis for an adolescent patient with oligodontia

Deepa Mukkai Krishnamurthy, Rajeev Singh, Gaurang Mistry

Department of Prosthodontics, School of Dentistry, DY Patil University, Navi Mumbai, Maharashtra, India

### Abstract

Oligodontia is a developmental anomaly which represents the congenital absence of more than six teeth in primary, permanent, or both dentitions and may or may not be associated with a syndrome. These patients suffer from occlusal disharmony, problems in speech and esthetic appearance. A multidisciplinary approach becomes mandatory to manage such patients to rehabilitate their oral function. Therefore, early diagnosis and treatment become important. This is a case report of a 15-year-old female patient with oligodontia, who was rehabilitated with removable overlay prostheses fabricated digitally, without modifying her existing dentition, to restore mastication, phonetics, and esthetics. Such an approach is essential for children who have not completed their growth. The monolithic three-dimensional (3D) printed denture has increased fracture resistance and higher wear resistance compared to conventional denture. It can also be easily adjusted, repaired and if required, reproduced. This article highlights the methodology, pros and cons of fabricating 3D printed dentures for such patients.

**Keywords:** Interim prosthesis, oligodontia, overdenture, overlay denture, polymethyl methacrylate denture, three-dimensional printing

**Address for correspondence:** Dr. Deepa Mukkai Krishnamurthy, A603, Jagat Vidya Apartments, MK Marg, Kala Nagar, Bandra East, Mumbai - 400 051, Maharashtra, India. E-mail: [deepa.mdc@gmail.com](mailto:deepa.mdc@gmail.com)


**Submitted:** 31-Jan-2021, **Revised:** 20-May-2021, **Accepted:** 03-Jun-2021, **Published:** 10-Aug-2021

### INTRODUCTION

Oligodontia is a developmental anomaly which is seen as the congenital absence of more than six teeth in primary, permanent, or both dentitions. Such patients usually face problems associated with mastication, phonetics, and esthetics. A multidisciplinary approach is often indicated for their rehabilitation which includes orthodontic, maxillofacial surgery, and prosthodontic treatment. The method adopted depends on the severity of the condition. The prosthesis fabricated for children includes removable acrylic prosthesis, either complete or partial.<sup>[1]</sup>

The removable heat cure acrylic partial denture needs to be replaced within 3.5–4 years on an average, due to dissatisfaction with the appearance, fracture, wear, or oral changes.<sup>[2]</sup> Overdentures and their modifications have also been used for these patients to restore their esthetics and function. The advantages being it helps rehabilitate without altering the existing dentition and be easily repaired or readjusted. The main disadvantages are the risk of fracture or wearing of the teeth with use.

Advancement in technology has improved the material and technique available to produce prosthesis with better

Access this article online	
<b>Quick Response Code:</b> 	<b>Website:</b> <a href="http://www.j-ips.org">www.j-ips.org</a>
	<b>DOI:</b> 10.4103/jips.jips_43_21

This is an open access journal, and articles are distributed under the terms of the Creative Commons Attribution-NonCommercial-ShareAlike 4.0 License, which allows others to remix, tweak, and build upon the work non-commercially, as long as appropriate credit is given and the new creations are licensed under the identical terms.

**For reprints contact:** [WKHLRPMedknow\\_reprints@wolterskluwer.com](mailto:WKHLRPMedknow_reprints@wolterskluwer.com)

**How to cite this article:** Krishnamurthy DM, Singh R, Mistry G. Interim three-dimensional printed overlay prosthesis for an adolescent patient with oligodontia. *J Indian Prosthodont Soc* 2021;21:304-7.

properties. One such innovation is three-dimensional (3D) printing.<sup>[3]</sup> Digital designing and 3D printing of the denture<sup>[4]</sup> has revolutionized prosthodontics. The main advantage is the improvement in flexural strength and impact resistance as the entire prosthesis is printed as a monolith. The flexural strength of 3D printed polymethyl methacrylate (PMMA) is 100–130 MPa and flexural modulus is 2400–2600 MPa.<sup>[5]</sup> For the heat cure acrylic, these values are 69 MPa and 1600 MPa, respectively.<sup>[6]</sup> The cost of 3D printing a prosthesis is lower when compared to computer-aided design/computer-aided manufacturing. Digital designing also helps us to establish optimal occlusal contacts for the patient with minimum processing errors.<sup>[7]</sup>

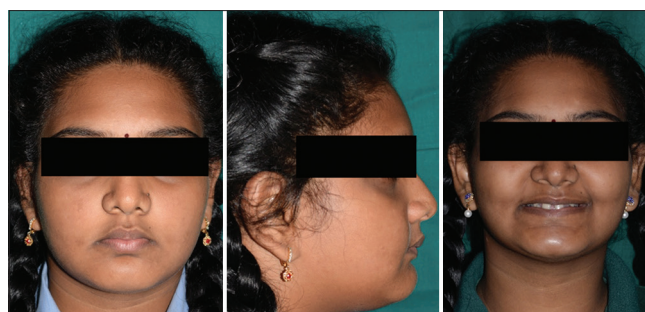### CASE REPORT

A 15-year-old girl reported with the chief complaint of difficulty in chewing food and dissatisfaction with her appearance. Extraoral examination showed drooping corners of the lips and prominent mentolabial fold [Figure 1]. There was no abnormality of the skin, hair, or nails. Family history revealed consanguineous marriage of parents. On dental examination, there were seven teeth in the upper and six in the lower arch. The upper incisors were permanent teeth while the rest were retained deciduous. Some teeth were peg-shaped and there was generalized spacing [Figure 2]. Based on the history and findings, she was categorized as a case of nonsyndromic oligodontia.

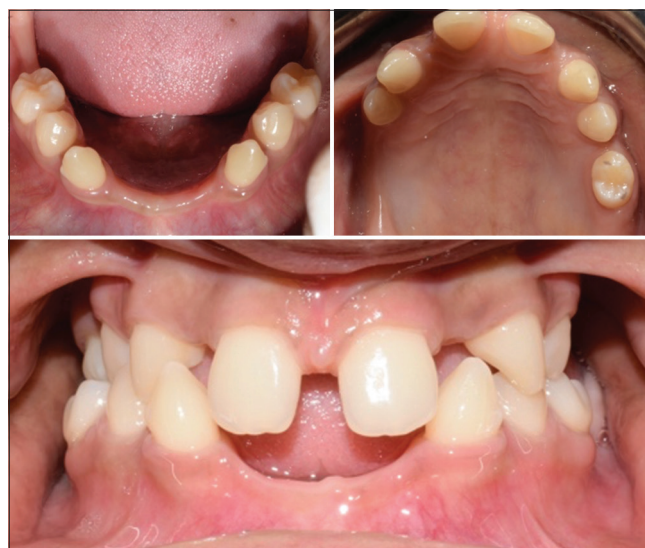The orthopantomogram [Figure 3] showed no impacted permanent teeth. Analysis of the hand and wrist radiograph [Figure 3] revealed scope for growth spurt in future as nonfusion of the middle phalanx of the third finger was seen. This helped us avoid permanent modification of her natural dentition.

A diagnostic mounting helped finalize the treatment plan. A removable prosthesis was planned for the patient given the age and radiographic findings. The tentative jaw relation and the extraoral findings were suggestive of loss of vertical dimension. An overlay prosthesis was decided for the patient which will help restore the correct vertical dimension, thereby improving her function and esthetics. Given the advantages of digital printing of prostheses, a 3D printed overlay denture was planned as an interim prosthesis which would not require modification of her existing dentition.

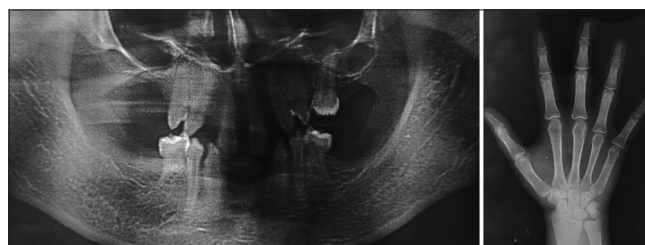Final impression was made using stock trays by conventional dentulous impression technique with addition silicone. On the models obtained, undercuts



**Figure 1:** Preoperative extraoral picture of the patient



**Figure 2:** Intraoral view of the maxilla and mandible and the occlusion



**Figure 3:** Orthopantomogram and the hand and wrist radiograph of the patient

were blocked, occlusal rims fabricated and centric relation was recorded at the appropriate vertical dimension [Figure 4].

Thereafter a denture wax-up was done which was used to prepare a thermoplastic template for fabricating the trial denture. The existing dentition was not altered in any way other than rounding off the sharp cusp tips of lower canines to avoid stress concentration on the prosthesis. Auto-polymerizing acrylic (pink and white) trial denture was fabricated with the template to confirm the vertical, centric, phonetics, and esthetics [Figure 5]. Shade selection for teeth was as per her age and skin tone.

A long-term interim prosthesis was required for this patient with adequate strength and repairability. The 3D printed monolithic denture in PMMA (NextDent, Netherlands) was conducive for the same. In the laboratory, the mounted models were scanned with the trial denture in place to maintain the occlusal plane as established intra-orally. The design was done using the EXOCAD software (EXOCAD GmbH, Germany). The undercuts around the teeth were first blocked digitally followed by designing of the final prosthesis [Figure 6].

Once satisfied with all parameters, the denture was printed [Figure 7]. The characterization of the denture was done using *visio.lign* System (Bredent, Germany). The *visio.paint* was used for staining teeth, *bond.align* for bonding the various layers, and *crea.lign* for additional veneering layer which created a lifelike appearance of teeth. Final curing was done using Lumamat 100 (Ivoclar Vivadent, Liechtenstein) in which curing light does not generate heat, thereby, the characterization was not lost [Figure 7].

During denture insertion, the fit of the prostheses on the underlying teeth was assessed intraorally using Fit-Checker (GC Corporation, Tokyo, Japan) to check for any premature contact or areas of load concentration. This was followed by the assessment of occlusion, phonetics, and esthetics [Figure 8]. Post insertion instructions were given to the patient and regular follow-up advised. The patient easily adapted to the new

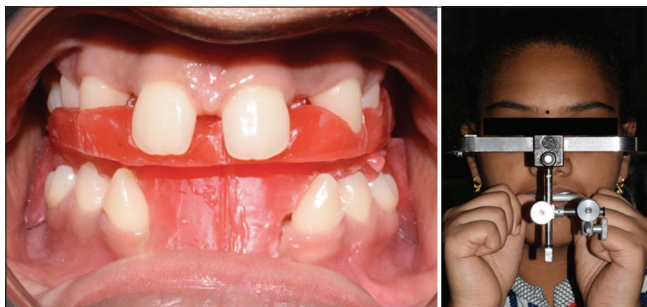denture and was able to masticate better. The clarity of speech improved in a week.

The maxillary denture retention at the 1-month follow-up was not as optimal as the mandibular denture. This was probably a result of extensive digital block-out during the denture fabrication. Auto-polymerizing PMMA powder and liquid were added to the intaglio surface of the denture and held in place on articulated model with adequately blocked undercuts.<sup>[8]</sup> The denture was retrieved, finished, polished, and checked in the patient. At the 2-months follow-up, she was satisfied with the denture [Figure 9].

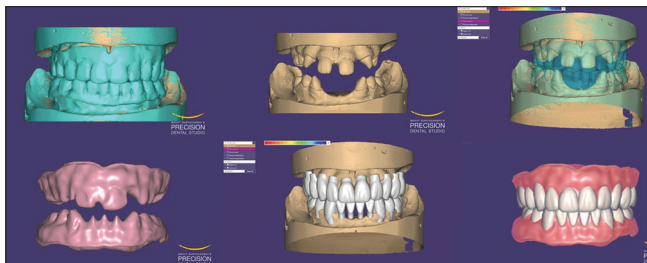
## DISCUSSION

PMMA or acrylic resin has been used for denture construction since 1937.<sup>[9]</sup> The innovative 3D printing technology has made possible the fabrication of denture as monolith with improved mechanical properties. The absence of interfaces in the prosthesis helps to improve fracture resistance.

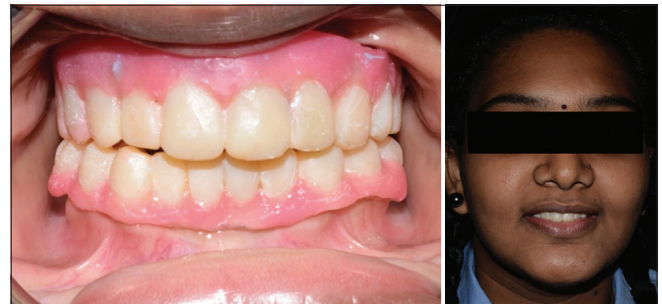The advantage of this prosthesis is the increased fracture resistance when compared to conventional overlay denture even though it is lighter in weight. The newer materials available allow for better characterization of the denture.



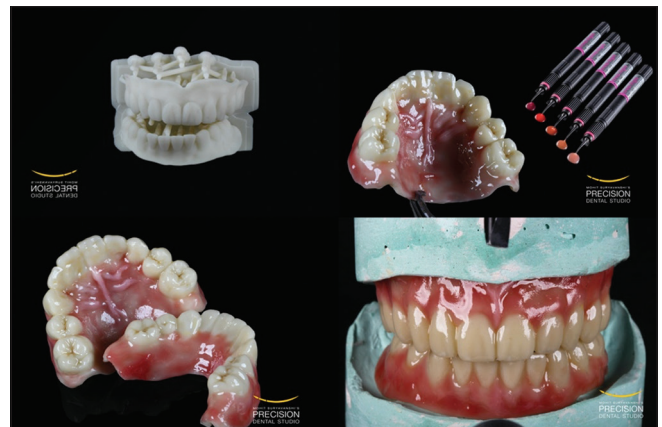**Figure 4:** Jaw relation record of the patient and face bow transfer recorded



**Figure 6:** Digital workflow of the case showing the scanning of the model and trial denture, blocking of undercuts and designing of the final denture

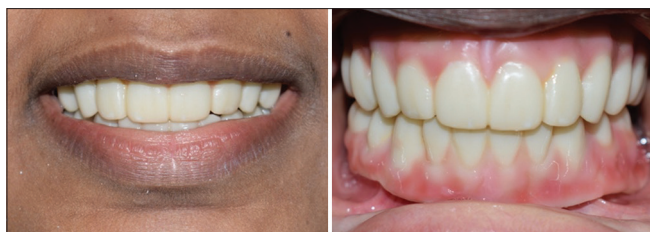

**Figure 5:** Trial denture made with the thermoplastic template



**Figure 7:** Characterization of the three-dimensional printed denture with *Visio.lign* system





**Figure 8:** Postoperative smile and occlusion of the patient

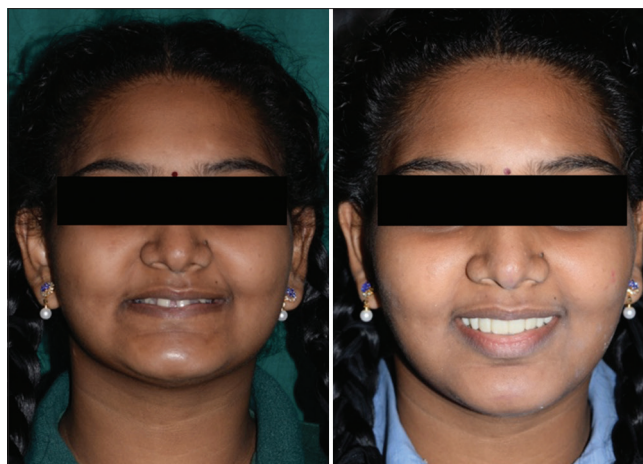In case of any natural tooth movement due to growth spurt, the denture can be easily adjusted. The intaglio surface of the denture can be trimmed to accommodate the movement of teeth and relined with PMMA of suitable shade after blocking the undercuts.<sup>[8]</sup> Being a digital file, it is also easy to reprint the same denture if required. As it is a removable prosthesis, it will not restrict the growth of the patient.

Increase in incidence of the dental caries is one of the major disadvantages of overdenture.<sup>[10]</sup> The patient was advised of fluoridated toothpaste and regular follow-up. The patient compliance may be compromised as young children need to be motivated to use a removable prosthesis. Specific to the technique employed, the main disadvantage was excessive block of undercuts which compromised the retentiveness of the maxillary denture. Hence it should be done judiciously.

This denture has greatly improved her mastication and the change in appearance has boosted her self-confidence. In future, she plans to get an implant-supported fixed prosthesis. Hence, it is recommended that in cases where early prosthetic reconstruction is essential, the aim should be to provide the patient with interim solutions which satisfy esthetic and functional requirements and avoid unnecessary damage to tissues. A long-term follow-up is required to establish the success of this prosthesis.

#### **Declaration of patient consent**

The authors certify that they have obtained all appropriate patient consent forms. In the form, the legal guardian has given his consent for images and other clinical information to be reported in the journal. The guardian understands that names and initials will not be published and due efforts will be made to conceal identity, but anonymity cannot be guaranteed.



**Figure 9:** Comparison of the pre and postoperative views

#### **Financial support and sponsorship**

Nil.

#### **Conflicts of interest**

There are no conflicts of interest.

#### **REFERENCES**

1. Teixeira Marques NC, Gurgel CV, Fernandes AP, Lima MC, Machado MA, Soares S, *et al.* Prosthetic rehabilitation in children: An alternative clinical technique. *Case Rep Dent* 2013;2013:512951.
2. Filius MA, Cune MS, Raghoebar GM, Vissink A, Visser A. Prosthetic treatment outcome in patients with severe hypodontia: A systematic review. *J Oral Rehabil* 2016;43:373-87.
3. Chander NG. An overview on 3D printing in prosthodontics. *J Indian Prosthodont Soc* 2020;20:121-2.
4. Anadioti E, Musharbash L, Blatz MB, Papavasilou G, Kamposiora P. 3D printed complete removable dental prostheses: A narrative review. *BMC Oral Health* 2020;20:343.
5. Revilla-León M, Meyers MJ, Zandinejad A, Özcan M. A review on chemical composition, mechanical properties, and manufacturing work flow of additively manufactured current polymers for interim dental restorations. *J Esthet Restor Dent* 2019;31:51-7.
6. Ajaj-Alkordy NM, Alsaadi MH. Elastic modulus and flexural strength comparisons of high-impact and traditional denture base acrylic resins. *Saudi Dent J* 2014;26:15-8.
7. Punj A, Kattadiyil MT. Management of ectodermal dysplasia with tooth-supported computer-engineered complete overdentures: A clinical report. *J Prosthet Dent* 2019;121:195-9.
8. Cooper LF, Culp L, Luedin N. A digital approach to improved overdentures for the adolescent oligodontia patient. *J Esthet Restor Dent* 2016;28:144-56.
9. Khindria SK, Mittal S, Sukhija U. Evolution of denture base materials. *J Indian Prosthodont Soc* 2009;9:64-9.
10. Nazar A, George R, Mathew N. Oral rehabilitation of a patient with Kenny-Caffey syndrome using telescopic overdenture. *J Indian Prosthodont Soc* 2021;21:204-7.